

# **ABDOMINAL WOUND**

**Abdominal Wound – Fournier Abscess**

**Female**

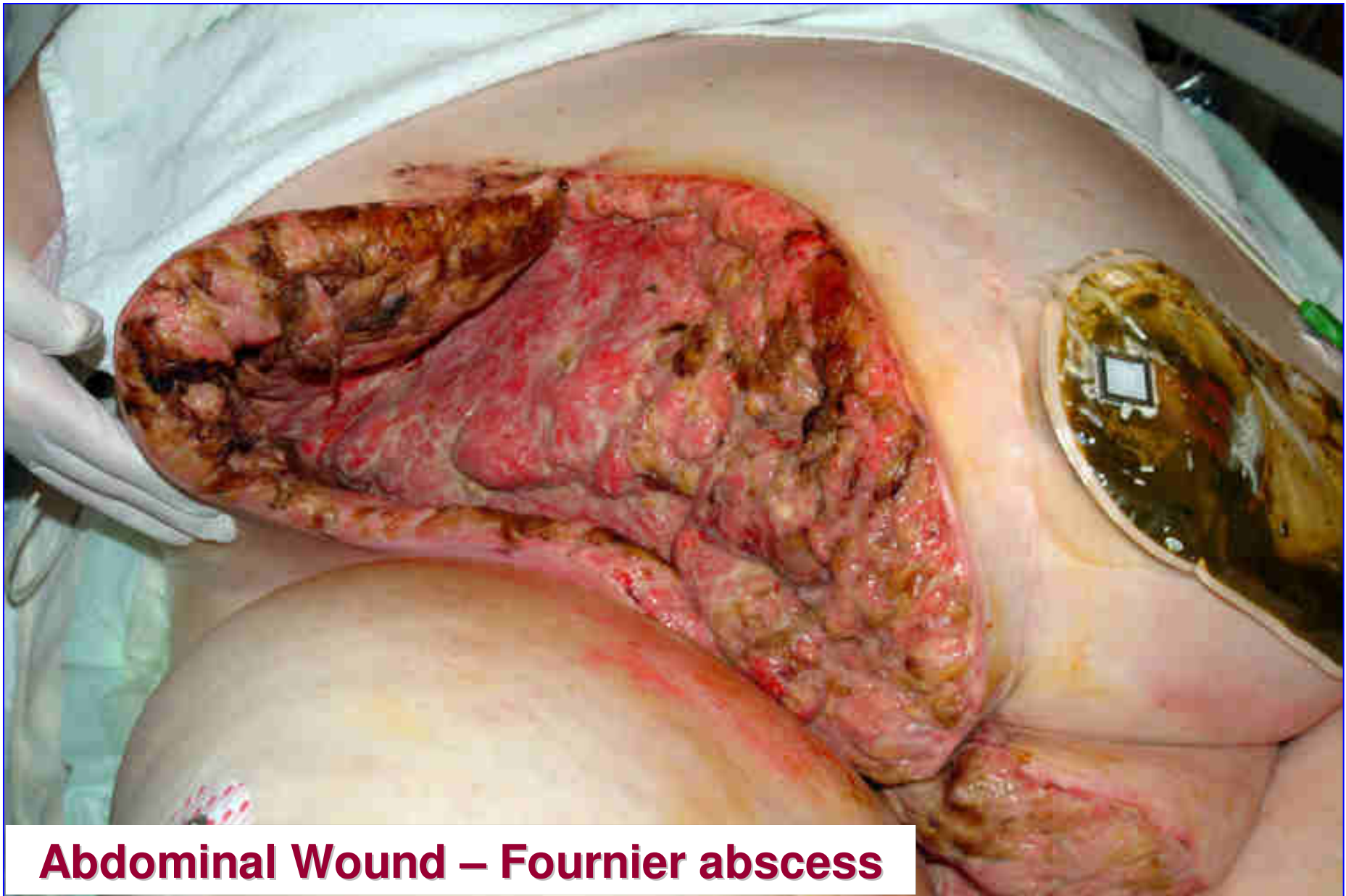
**Age: 71 Years**

**Start Q.Light<sup>®</sup>: 04/09/2006**

**Full Closure: 13/11/2006**

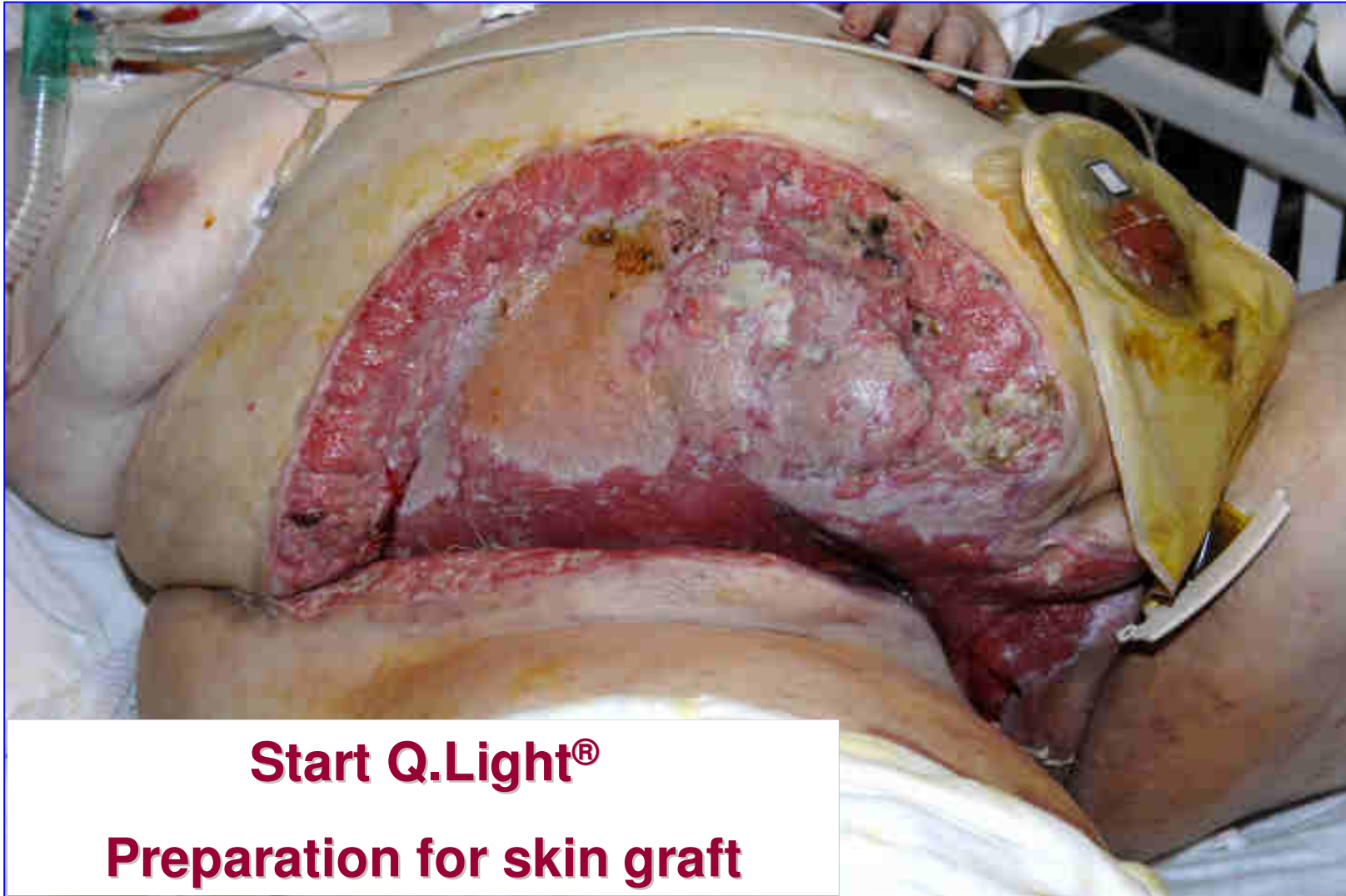**Total Treatment Time: 2 months**

**Treatment: 12 minutes daily**

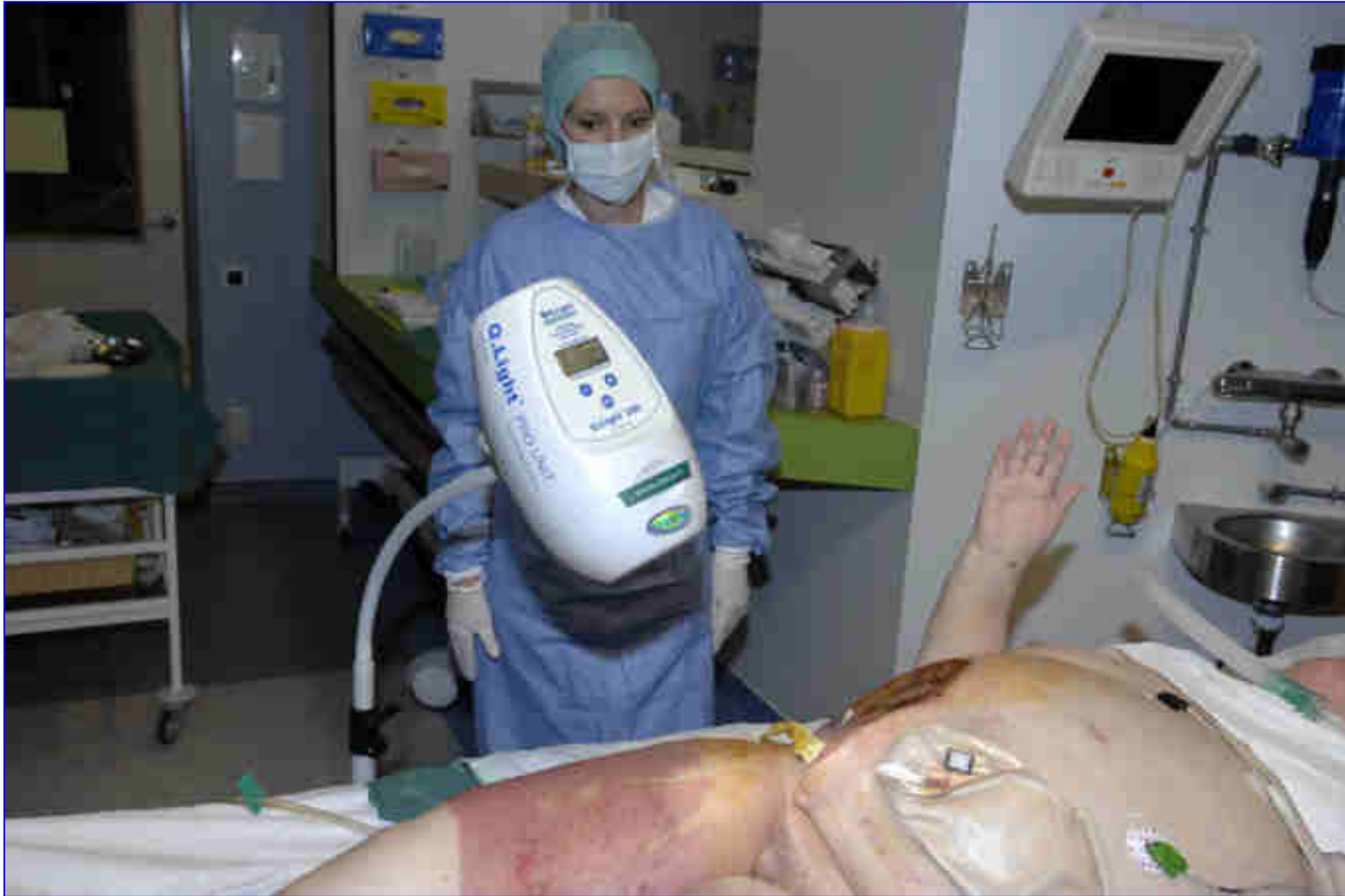

**Abdominal Wound – Fournier abscess**

# Skin Defects after Mesh Grafts



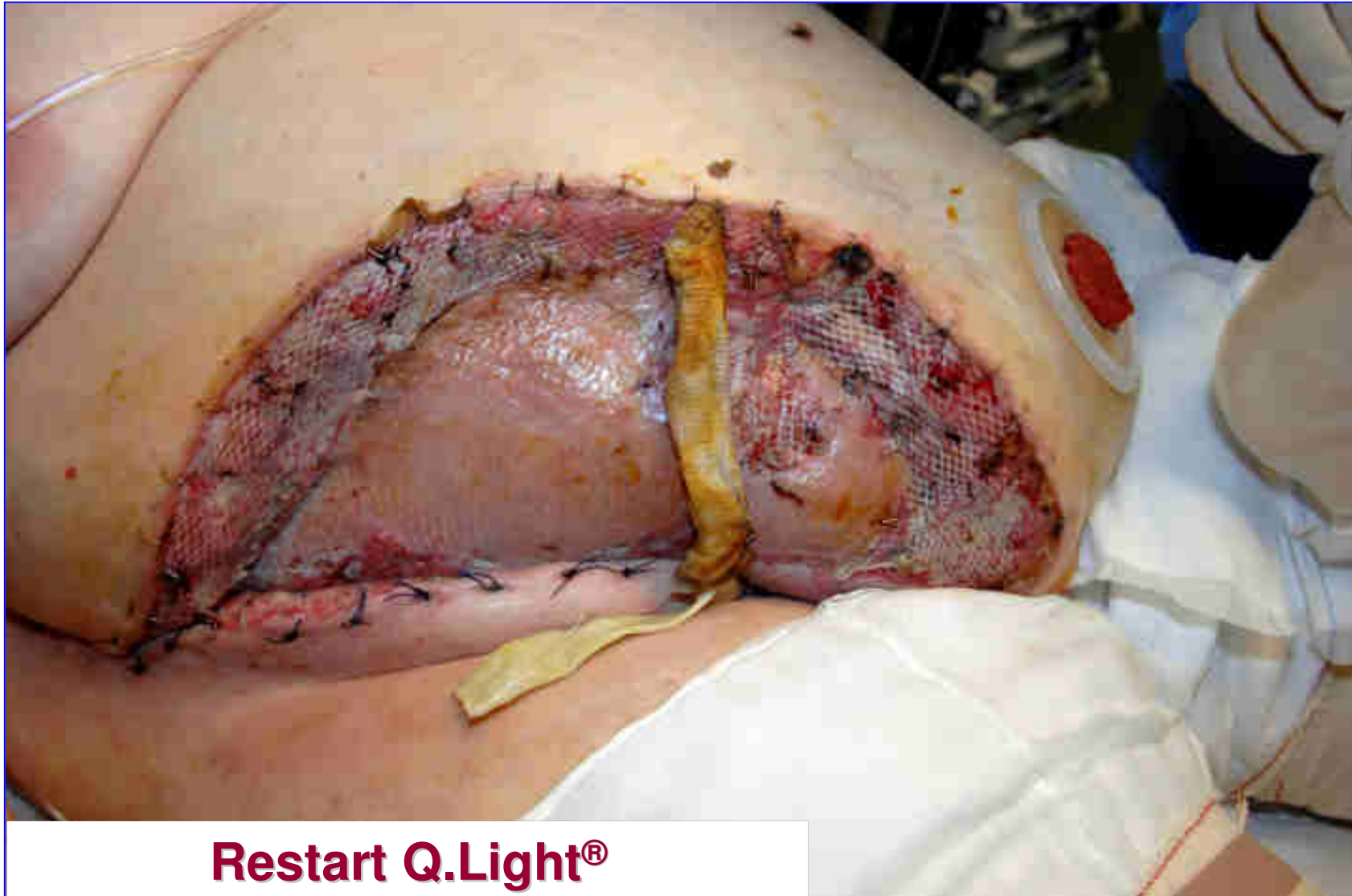
# Q.LIGHT®



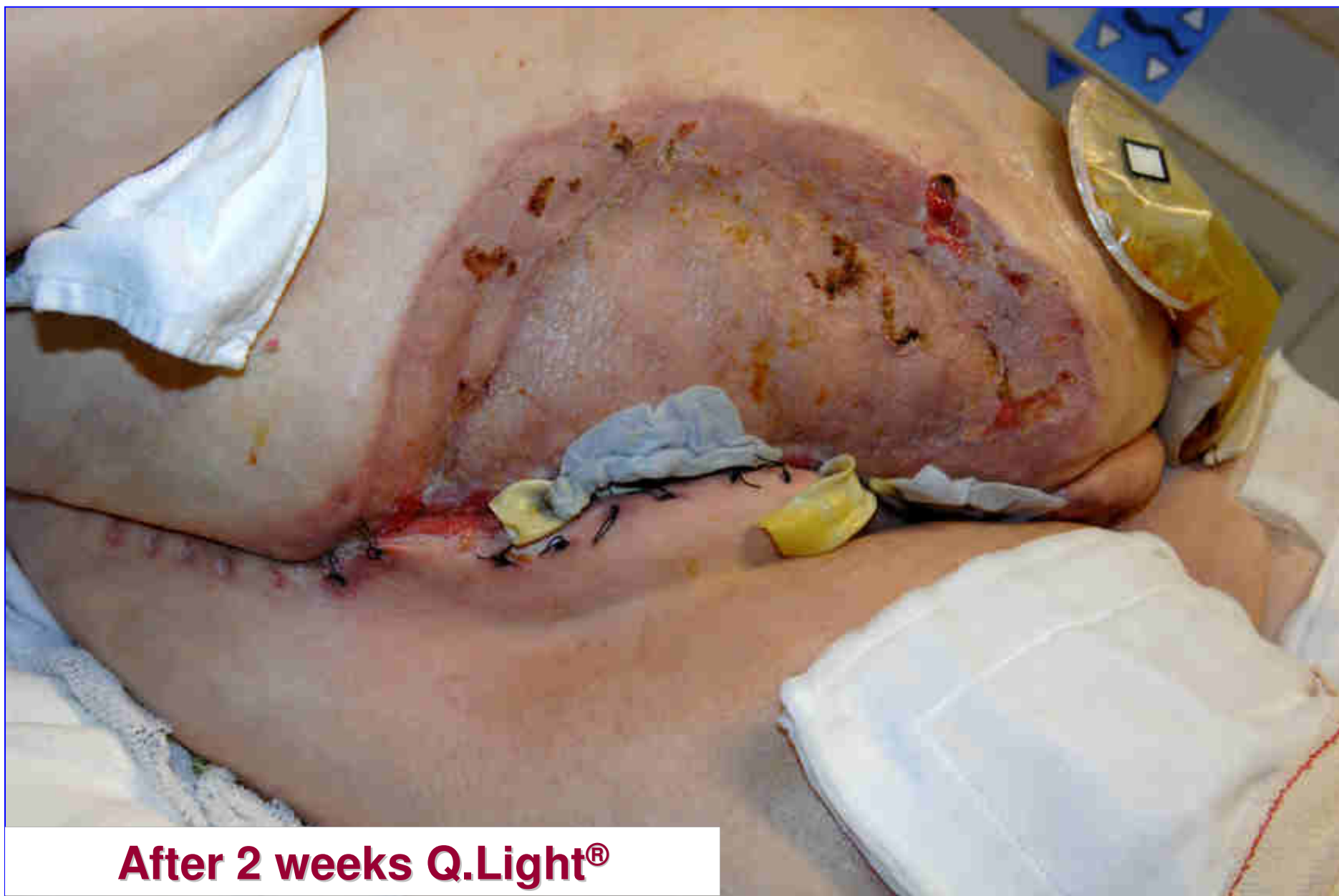Dept of Plastic & Reconstructive Surgery / University Hospital Gent



# Second mesh graft procedure

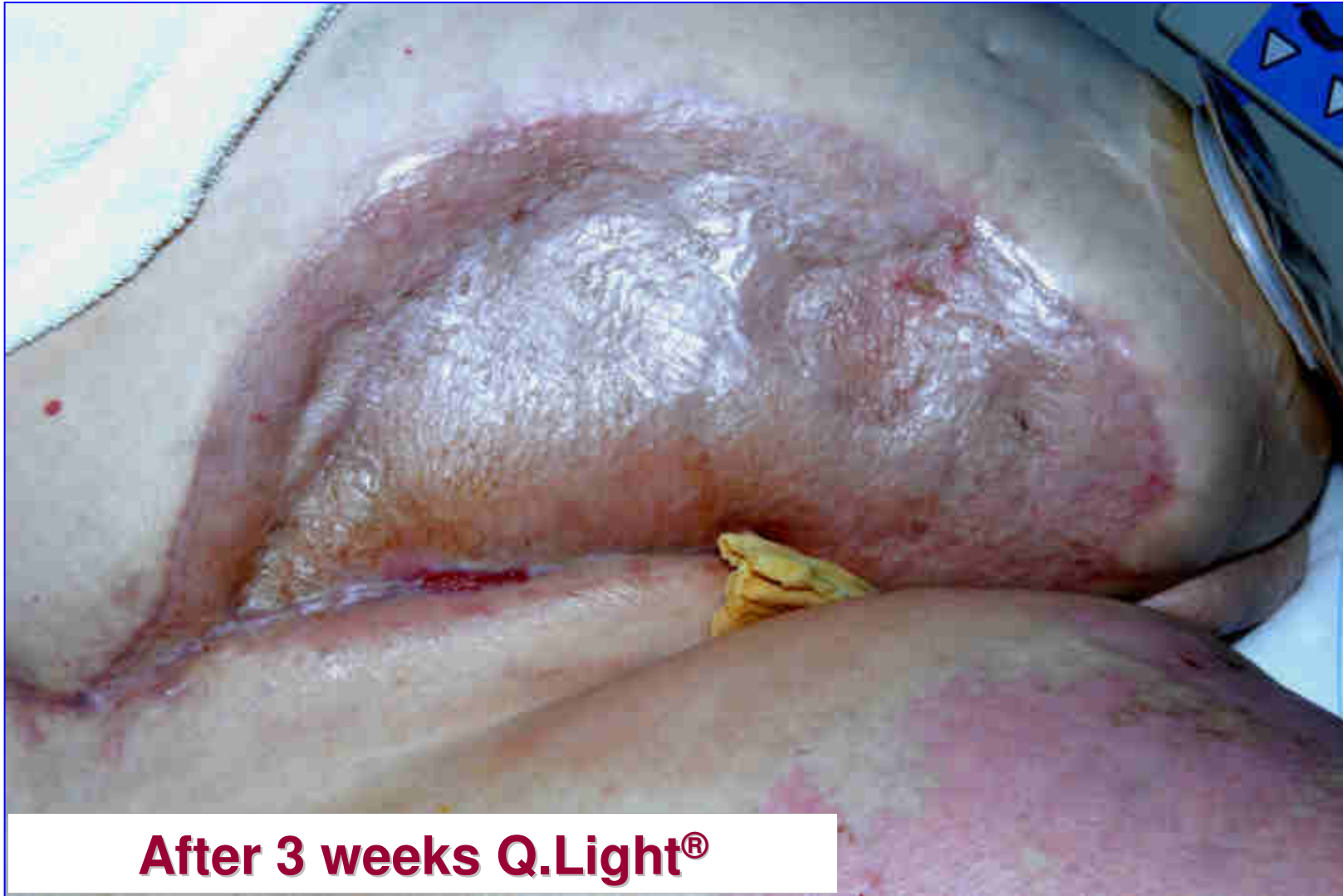

**Restart Q.Light®**

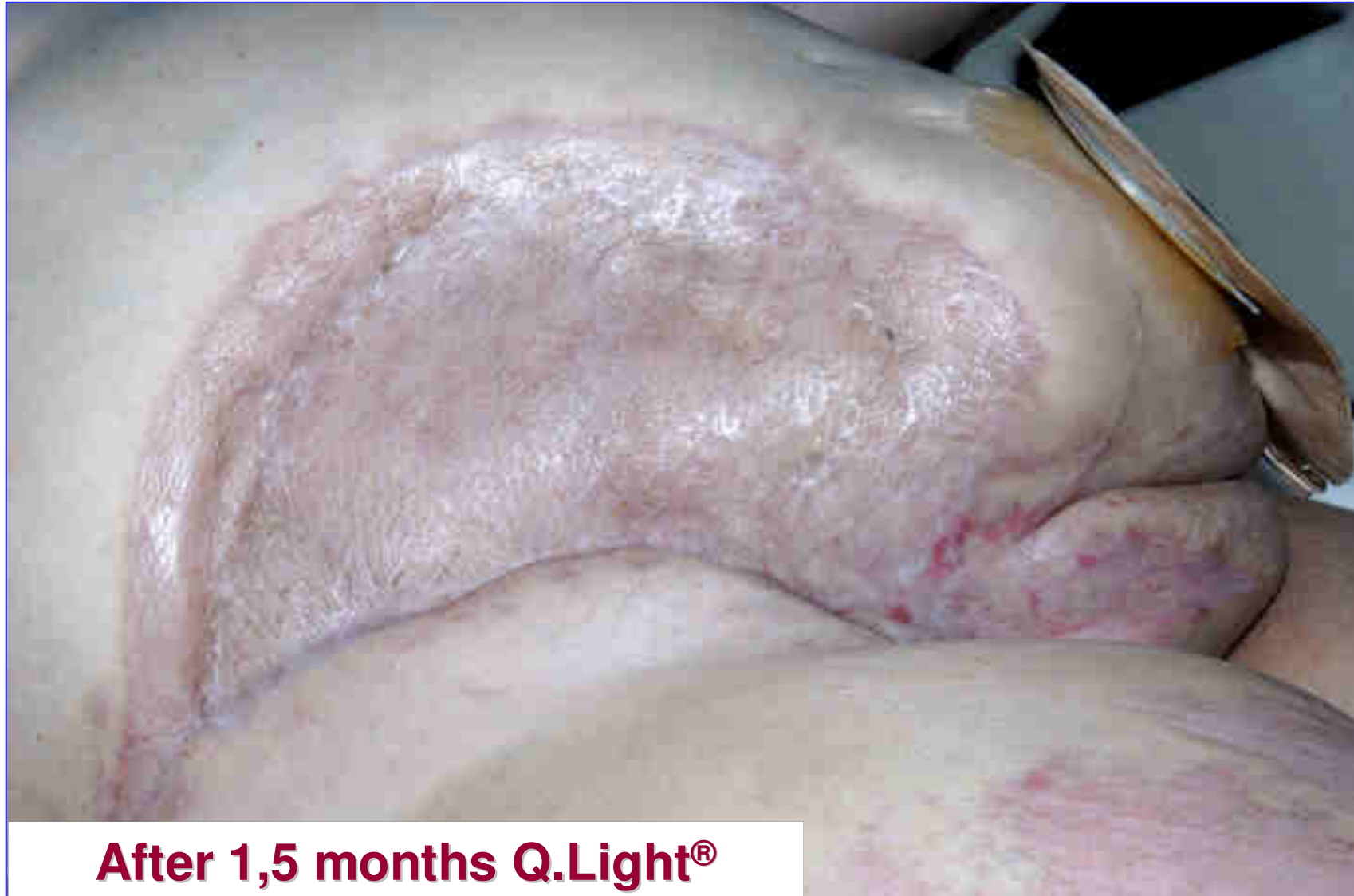

**After 2 weeks Q.Light®**

# Q.LIGHT®



# Q.LIGHT®



**After 1,5 months Q.Light®**